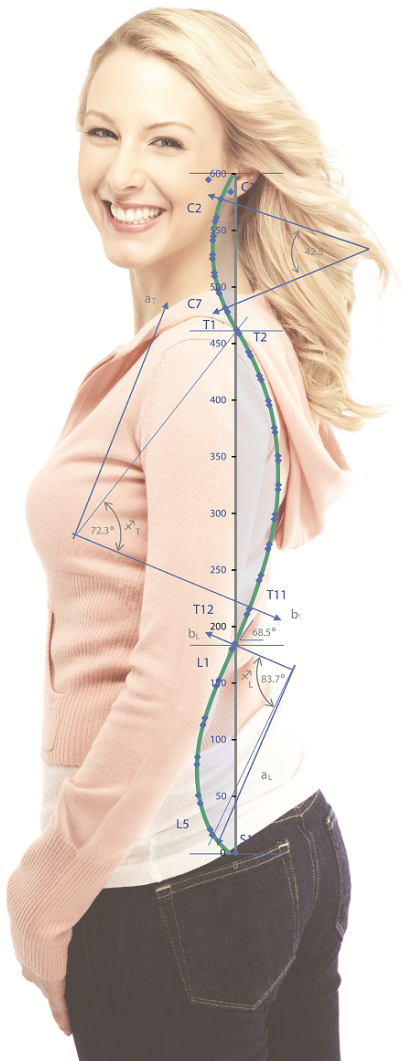




**PostureRay**<sup>®</sup>  
Exacting X-Ray Analysis

## X-RAY Report of Findings



Prepared for : Trent Ashburn

Evaluation Date : 11/16/2021

Date X-Ray Taken: 11/16/2021

Prepared by:  
Katz Chiropractic & Rehab Clinic  
2727 Pine Street Unit 1  
Boulder, Colorado  
80302

### Welcome

You have chosen to be a patient at an office that utilizes posture and x-ray to evaluate your spinal alignment. While a postural analysis can provide a knowledge of gross postural/spinal abnormalities (your outside alignment), only a radiographic evaluation can provide the details of your spine's alignment and condition (your inside alignment). Your spinal alignment, any possible spinal arthritis, and disc disease (S.A.D.D.) are both conditions of interest to your doctor. With the knowledge from analyzing your spinal x-rays, your health care provider can determine a beginning clinical impression (diagnosis from any abnormalities found on your x-rays) and determine an initial program of corrective care.

### What is Normal for the Spine?

Your doctor performs several levels of analyses on your spinal x-rays. First, an overall evaluation of your alignment in front-to-back radiographic views and your side radiographic views is performed. In the Front view, your spine should be straight or vertically aligned with gravity. In the Side view, your spine should have four natural curves. These four curves should be a convex forward curve in the neck (termed lordosis), a concave curve in the rib cage area (termed thoracic kyphosis), another convex forward curve in the low back (termed lumbar lordosis), and a concave curve in your sacrum-tailbone area. Figure 1 illustrates this alignment.

Figure 1.

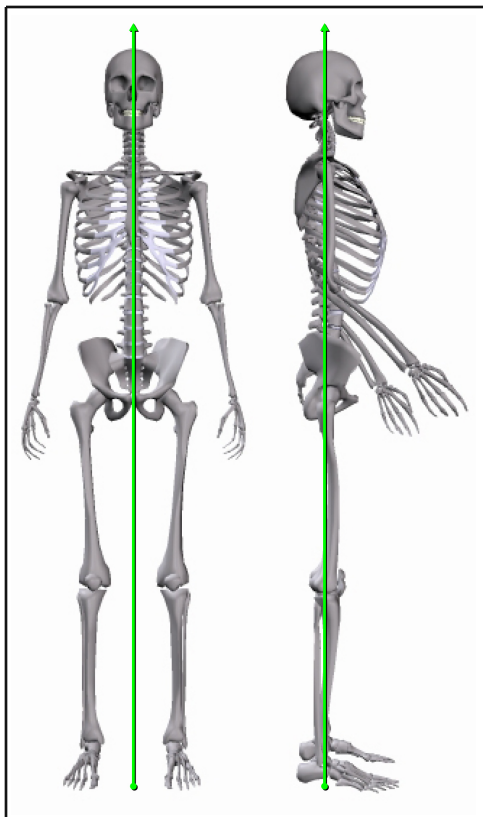


Figure 1.

Normal spinal alignment is depicted in both the front and Side views. In the front view, the center of mass of the skull, thorax, and pelvis are in a vertical line which falls between mid-stance. The spinal column is vertically aligned with respect to gravity. In the side view, the center of mass of the skull, thorax, and pelvis are in vertical alignment over the ankle. The cervical spine is lordotic, the thoracic spine is kyphotic, and the lumbar spine is lordotic.


# Katz Chiropractic & Rehab Clinic

2727 Pine Street Unit 1, Boulder, Colorado 80302 303-938-9070

## X-RAY Report of Findings

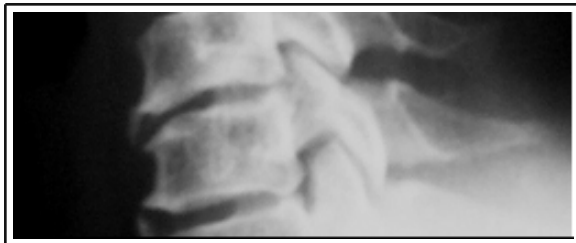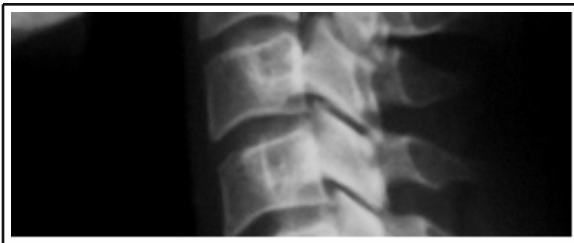## Introduction

For a second evaluation, your doctor looks for any obvious spinal ligament damage by observing individual spinal vertebra for any left or right misalignments in the front view and any forward or backward misalignments in the side view. Figure 2 illustrates cases of spinal ligament damage.

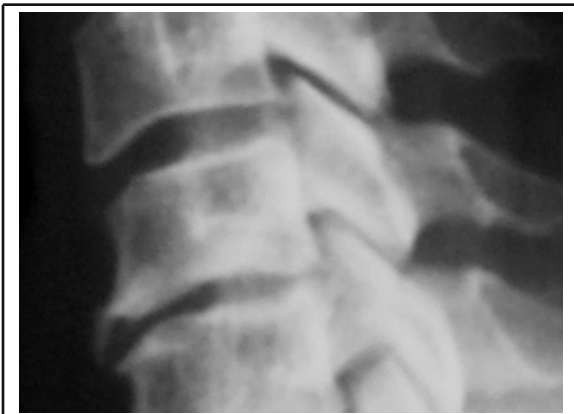

**Figure 2.** Ligament damage is present when a spinal vertebra does not align properly with either the vertebra immediately above it or immediately below it. In the 1st and 2nd picture, abnormal alignment of a vertebra translating left and right, signifying spinal ligament damage, is illustrated for the front view. In the 3rd picture, in the side view, backward slippage of the top vertebra is depicted. In the 4th picture, in the side view, forward slippage is shown.

For a third evaluation of your spinal x-rays, your doctor checks each vertebra for normal contour and density. This evaluation determines the state of any possible spinal arthritis and disc disease (S.A.D.D.) that you may have. Figure 3 provides an example of this analysis.



For a fourth evaluation of your spinal x-rays, your doctor checks the spacing between each pair of vertebrae. This spacing is where the spinal discs lie. Any narrowing of the normal spacing indicates disc injury and disc disease. Figure 4 presents an example of disc narrowing and disease.



**Figure 4.** Between the top and middle vertebrae, a normal disc spacing is seen. However, between the middle and lower vertebrae, the disc space is narrowed. This indicates that the disc has been injured and is losing its water content. While disc disease can have several causes, generally, it is a result of abnormal stress (pressures) applied to the disc from abnormal spinal alignment.

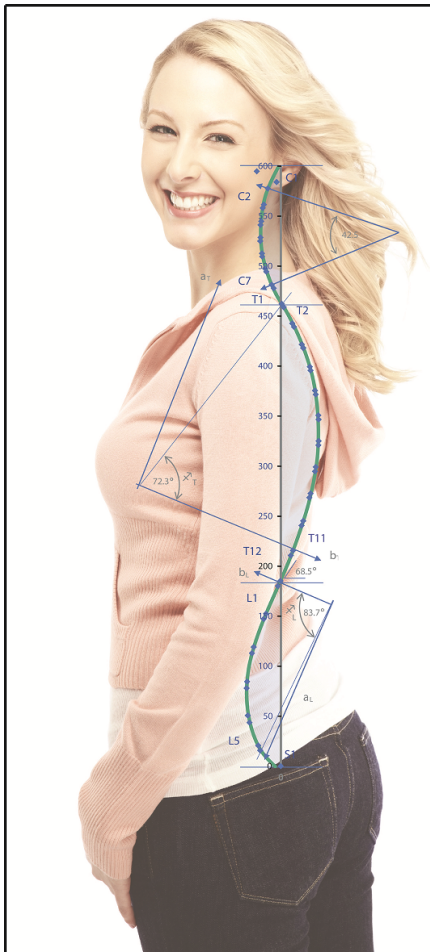
# Katz Chiropractic & Rehab Clinic

2727 Pine Street Unit 1, Boulder, Colorado 80302 303-938-9070

## X-RAY Report of Findings

## Introduction

For a fifth evaluation of your spinal x-rays, your doctor determines the alignment of each spinal region (neck, rib cage, and low back) compared to the region immediately below by comparing each region to a vertical line in both the front view and side view. The following vertebrae should be vertically aligned with each other: C1 (first neck vertebra), T1 (first rib cage vertebra), T12 (last rib cage vertebra at the level of your kidneys), and S1 (first vertebra in your sacrum). Figure 5 illustrates this alignment for the three separate spinal regions, neck, rib cage, and low back.



**Figure 5.**

Normal spinal balance from the side is when a vertical line will pass through C1, T1, T12, and S1. This can be observed all at once on a full-spine side view x-ray or for individual regions on smaller x-ray views, termed sectional x-rays. The figure to the left shows only the posterior points of each vertebra. If we look at the side view cervical (neck), C1 is aligned with T1 (thick vertical black line), with a forward convex curve termed cervical lordosis. If we just look at the side view of rib cage (thoracic), T1 is aligned with T12 and there is the presence of a concave curvature (termed thoracic kyphosis). If we look at the side view lumbar (low back), T12 is aligned with S1, with a forward convex curve termed lumbar lordosis.

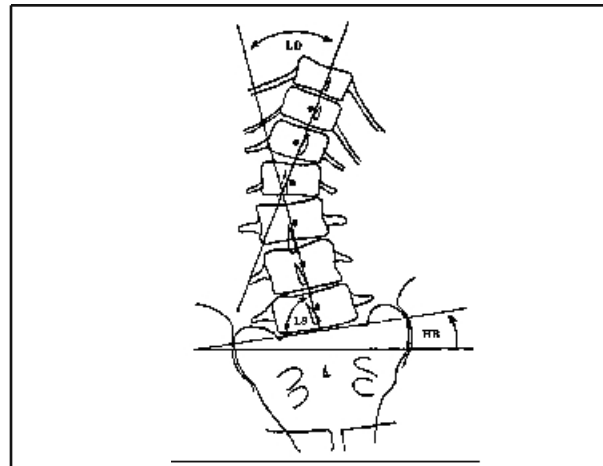
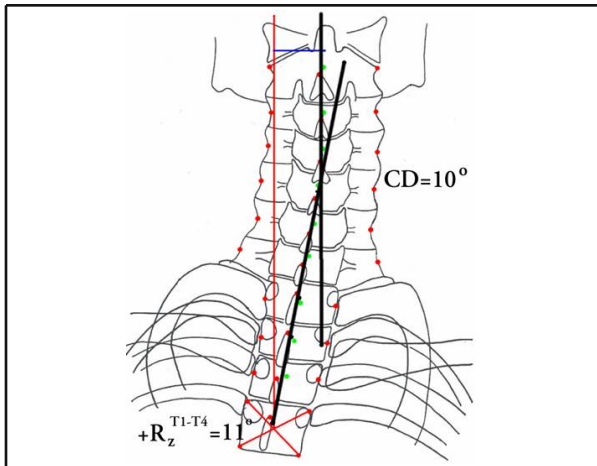
For a sixth evaluation, your doctor measures any displacements of the individual spinal vertebra and/or spinal regions. These measurements are in degrees for any angular or turning (rotational) displacements and in millimeters for any sliding or shifting (translational) displacements. Figures 6 and 7 illustrate these measurements.

# Katz Chiropractic & Rehab Clinic

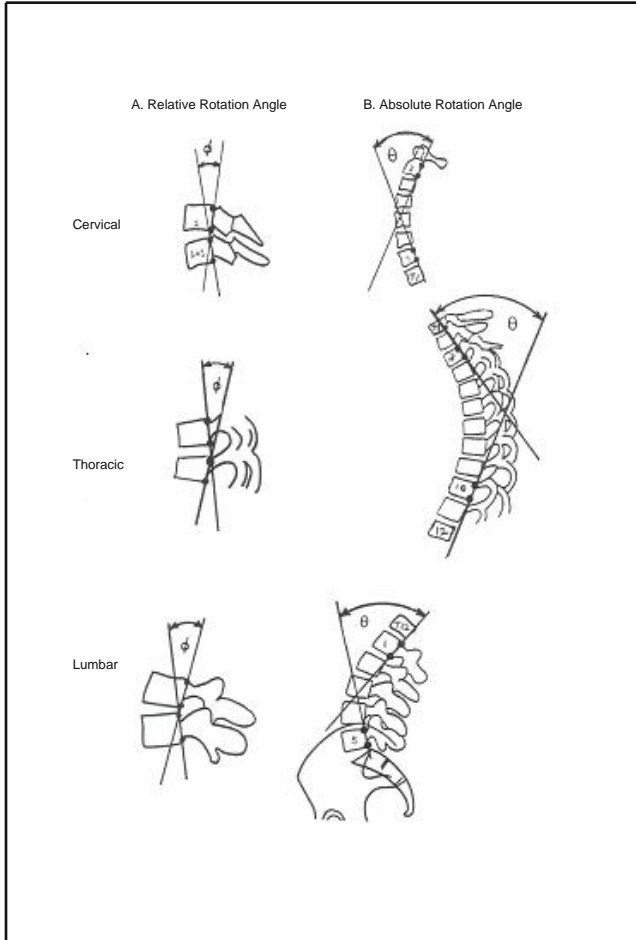
2727 Pine Street Unit 1, Boulder, Colorado 80302 303-938-9070

## X-RAY Report of Findings

## Introduction



**Figure 6.** In the front x-ray views, lines are drawn through the centers of mass of each spinal vertebra to measure your abnormal spinal alignment. In A, an example of an analysis of abnormal spinal alignment of the neck in the front view is provided, and in B, an example of an analysis of abnormal spinal alignment of the low back is shown.



**Figure 7.**

In the side view, lines are drawn on the back part of each spinal vertebra. These lines are termed "Posterior Tangents". When measuring angles between adjacent posterior tangents, the angles are termed Relative Rotation Angles (RRA). When angles are formed by posterior tangents on the top and bottom vertebrae in any spinal region, these angles are termed Absolute Rotation Angles (ARA). There are precise normal values published in the scientific literature for each spinal RRA and each spinal ARA. Your alignment will be compared to these published normal values.



### What Are the Risks of X-ray Exposure?

While we must constantly work towards the reduction of health risks in all endeavors, we may be led to accept a minimal level as normal. While there is no data indicating diagnostic radiology has a present risk, any radiation dose must be compared to the benefits of useful information gained. The necessity for appropriate treatment selection is indeed an acceptable trade-off when put into perspective. The need for x-ray imaging is especially clear when one considers that radiographic (x-ray) imaging is the only valid method for determining abnormal spinal alignment and the presence of any spinal degeneration. However, since 1990, there has been a growing knowledge base that suggests medical x-rays may have health benefits. While an actual benefit from radiation exposure may seem outrageous, there is much scientific evidence for this phenomenon. This phenomenon/field of study is termed Radiation Hormesis.<sup>[12-27,29-48]</sup>

Radiation Hormesis is the stimulatory or beneficial effect of low doses of ionizing radiation. This topic is in direct conflict with the "Linear No-Threshold Hypothesis" (LNT), which has been assumed to be true for more than 50 years. This LNT model comes from estimating the risks at lower doses of radiation, in the absence of data, by extrapolating in a linear model from the extremely large doses of radiation from atomic bombs dropped on Japan in the 1940s.

This LNT model has been used to set limits of radiation exposure by all official and governmental associations around the world.<sup>[17]</sup> Recently in 2003, Kauffman<sup>[12]</sup> reiterated that authors critical of exposure from diagnostic radiation always use the LNT model. This use of the LNT model includes the recent 2005 report by the USA National Research Council.<sup>[28]</sup> This report stated, "there will be some risk, even at low doses (100 mSv or less), although the risk is small" and "there is no direct evidence of increased risk of non-cancer diseases at low doses."<sup>[28]</sup> This 2005 report ignored and contradicted an earlier 2003 review by Kant et al.<sup>[29]</sup>

For a comparison of exposures, USA citizens are exposed to an average annual natural background radiation level of 3 mSv, while exposure from a chest x-ray is approximately 0.1 mSv and exposure from a whole body computerized tomography (CT) scan is approximately 10 mSv.<sup>[28]</sup> Also it is noted that 10mSv = 1,000mrem, which equates to about 46 cervical series or 8 lumbar series. Thus, the x-ray views taken to evaluate your spine in this office constitute a very small exposure compared to a CT scan or even annual background radiation from your natural environment.

Thus, it is obvious that the extremely small health risks (and maybe even some health benefits), associated with the x-ray exposure, needed to determine the state of health of your spine in this Report, are small indeed compared to the knowledge gained from this information.

From your radiographic examination at our office, we have determined the state of degeneration of your spine, and have determined the exact displacements of your spine. This knowledge not only gives us a working Clinical Impression/diagnosis of your spinal condition, but also determines the type of treatment that is needed to improve your spinal health condition.

We hope that you appreciate our thoroughness in examining and diagnosing your spinal health problems. In the next few pages, for each x-ray view obtained, we will present a normal view on the left hand side to compare to your x-ray on the right hand side. A table of values of normal measurements and your abnormal alignment will be provided on a Summary page after the x-ray photographs.

# Katz Chiropractic & Rehab Clinic

2727 Pine Street Unit 1, Boulder, Colorado 80302 303-938-9070

## X-RAY Report of Findings

## Introduction

### This Analysis Has Been Researched

We are proud to state that the normal spinal alignment presented in this report is the result of many research projects on spinal alignment in normal subjects.<sup>[1-6]</sup> Normal values for all spinal angles and distances, utilized in this report, have been reported in the most prestigious journals in the Index Medicus literature.<sup>[1-6]</sup> Your abnormal spinal displacements (subluxations) will be compared to these normals.

These measurements of spinal displacements, utilized here, are mathematical utilizing geometric methods. This geometric line drawing analysis has been shown to be very reliable (repeatable) and valid (accurate).<sup>[7-11]</sup>

### Clinical Impression/Diagnosis

A Clinical Impression (Diagnosis) of your condition is derived from a variety of sources, including the consultation and discussion of your health history with your doctor, any orthopedic and/or neurological examinations, range of motion examination, postural examination, and the radiographic examination.

For recordkeeping purposes, the Clinical Impression is reduced to numerical codes, which have been agreed upon world wide. These International Classification of Diseases codes are termed "ICD" codes, are given to healthcare providers in code books, and are lists of specific agreed upon numbers followed by brief descriptions. These numbered ICD codes make for easy communication of your health problems, when given to any third party payers or state government entities, i.e., insurance companies, Workers Compensation, lawyers, courts, State Boards, etc.

Generally, a patient can trace his/her present condition back to a past injury, which is termed mode of onset. Using ICD codes, your doctor has reduced your condition to 5 different categories: (1) mode of onset of condition (accidents, falls, etc), (2) global postural displacements, (3) regional and/or segmental spinal displacements, (4) unchangeable complicating factors (ligament damage, spinal fractures, osteoarthritis, etc), and (5) disease syndromes (headaches, neck pain, arm pain, mid back pain, low back pain, leg pain, sciatica, etc.).

# Katz Chiropractic & Rehab Clinic

2727 Pine Street Unit 1, Boulder, Colorado 80302 303-938-9070

## X-RAY Report of Findings

## Side View of Your Neck (Lateral Cervical View)

### The normal healthy curvature of a neck from the side.

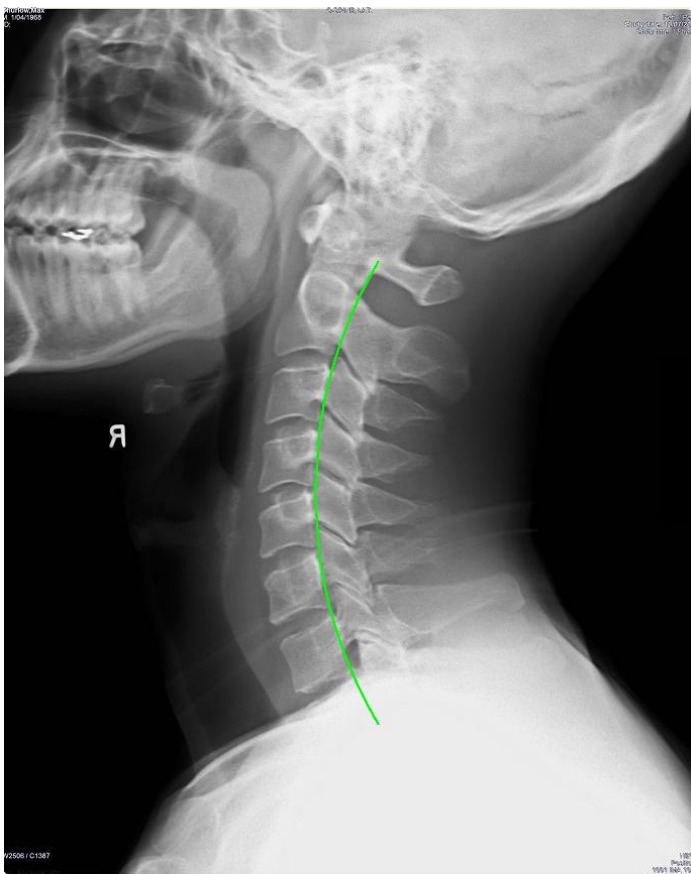
The green curved line represents the normal, healthy position for your neck.

No spinal arthritis is apparent and healthy disc spaces are visualized.

### Your neck position from the side.

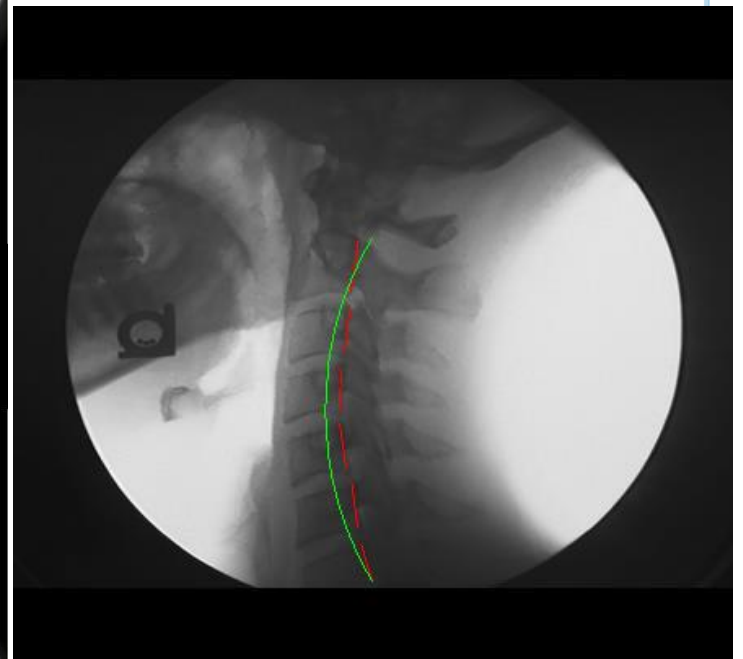
This green line represents the normal, healthy position for your neck.

This red line represents where your neck is currently positioned.



Front

Back



Front

Back

### Notes about your condition:

Your head is positioned 5.1 mm forward. Your neck curve measures  $-25.0^\circ$  and should be  $-42.0^\circ$  (a negative sign indicates lordosis or normal curve direction). This represents a 40.5% loss in your curve compared to the normal neck curve.

The abnormal position of your neck puts increased pressure on your spinal discs, muscles, bones, and nerves. Research has shown that abnormal neck curve positions are associated with early spinal arthritis and disc diseases (S.A.D.D.).



# Katz Chiropractic & Rehab Clinic

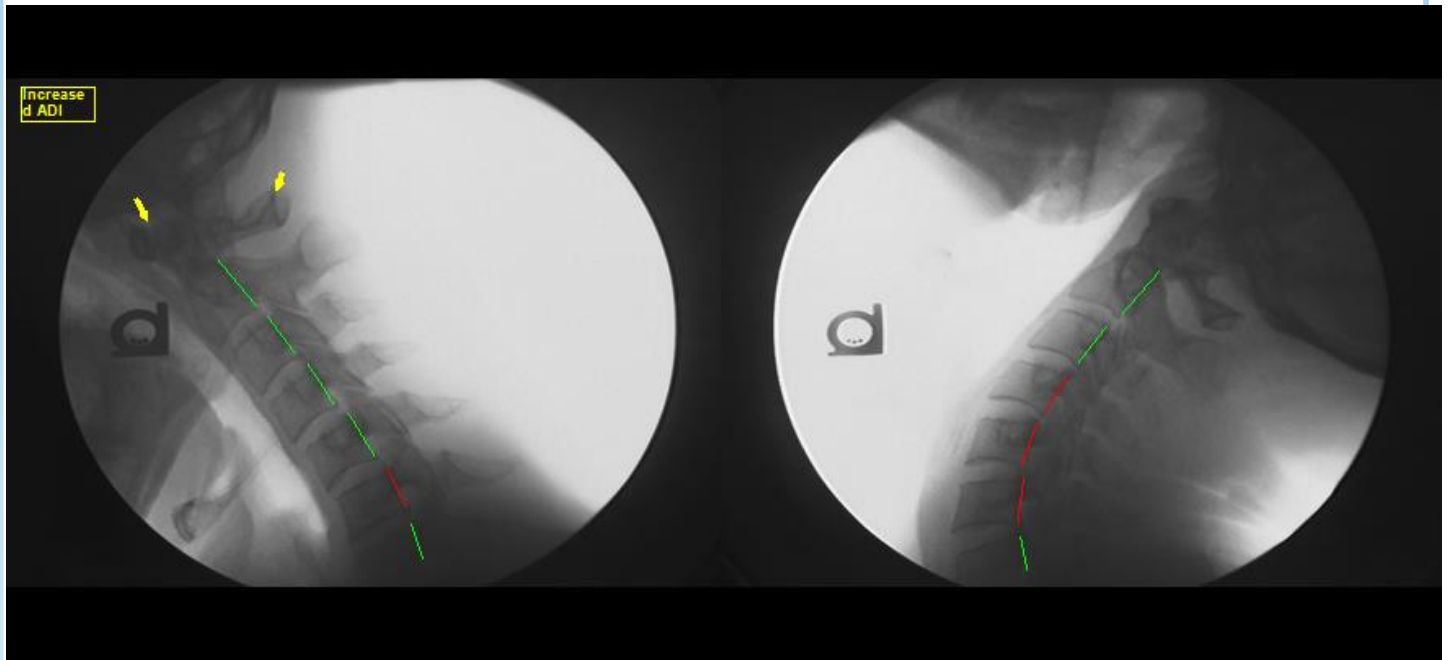
2727 Pine Street Unit 1, Boulder, Colorado 80302 303-938-9070

## X-RAY Report of Findings

## Side View of Your Neck Flexed and Extended (Lateral Cervical Flexion and Extension View)

This line represents where your neck is currently positioned with normal displacements.

This line represents where your neck is currently positioned with abnormal displacements.



Front

BackFront

Back

### Notes about your condition:

This x-ray is taken to observe the stability of your spinal ligaments when you bend your head forward and backwards. Ideally there should be minimal shifting of one vertebrae relative to the adjacent vertebrae. When spines are injured, it is common to see an abnormal increase in displacement slippage forward or backwards and/or an increase in angulation between

In your spine when you tip your head down (flexion position), you show possible damage at the C6-C7 spinal levels.

In the head backwards position (extension position), your spine demonstrates possible ligament damage at the C4-C5, C5-C6, C6-C7 spinal levels.

# Katz Chiropractic & Rehab Clinic

2727 Pine Street Unit 1, Boulder, Colorado 80302 303-938-9070

## X-RAY Report of Findings

## Front View of Your Upper Neck (AP Open Mouth View)

### The normal healthy position of the neck from the front.

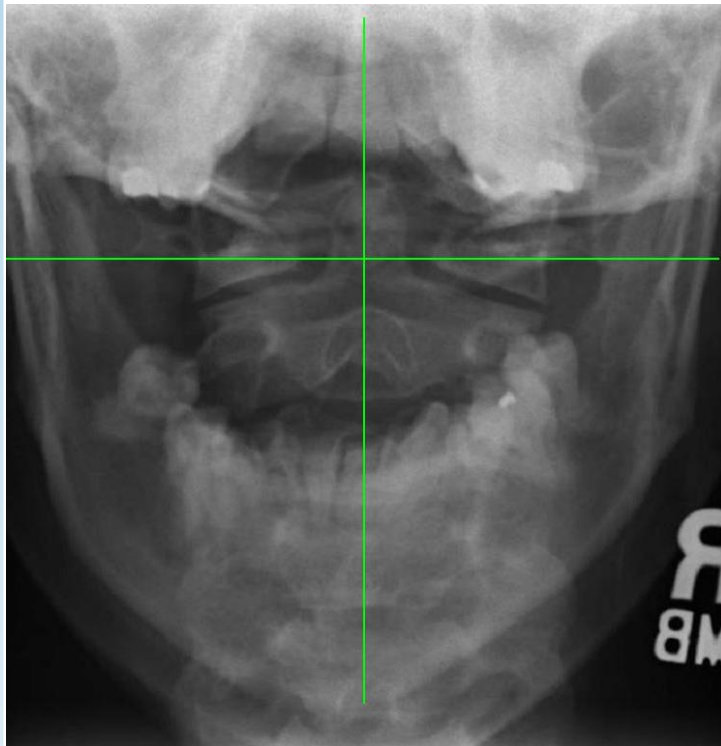
The horizontal line represents the normal atlas position. The vertical line is a plumb line, also indicating normal vertical spinal alignment.

No arthritis is apparent and healthy joint spaces are visualized.

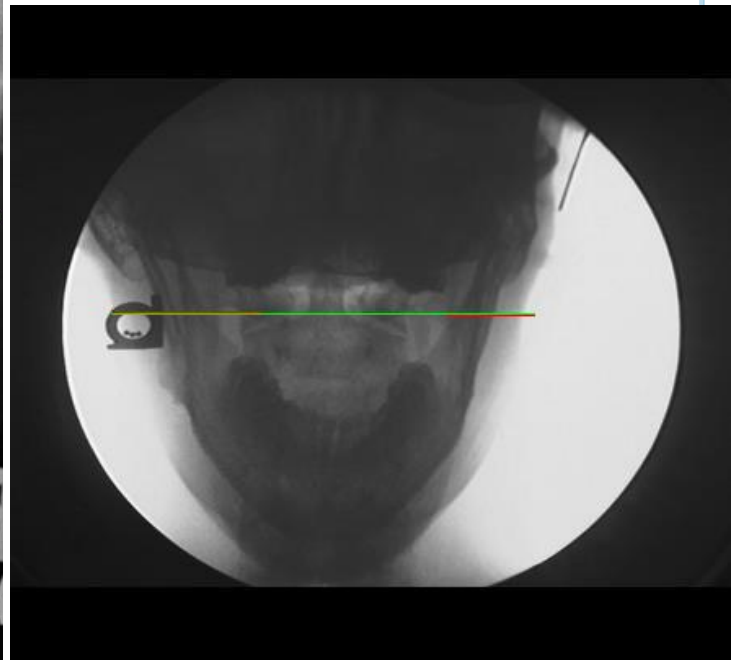
### Your neck position from the front.

The green line indicates the normal position for your spine.

The red line indicates the abnormal current position for your spine.



X-ray Left



X-ray Left

X-ray Right

X-ray Right

### Notes about your condition:

This x-ray is taken to mainly observe your upper neck position, the Atlas (C1 Vertebrae) and Axis (C2 Vertebrae). Ideally the Atlas should rest upon Axis in a perfect vertical and horizontal alignment as viewed on the normal x-ray example. Your spine demonstrates that the left side of your Atlas is shifted 0.7 mm left off of the Axis (C2), and on the right side is shifted 1.0 mm to the left of the Axis.

# Katz Chiropractic & Rehab Clinic

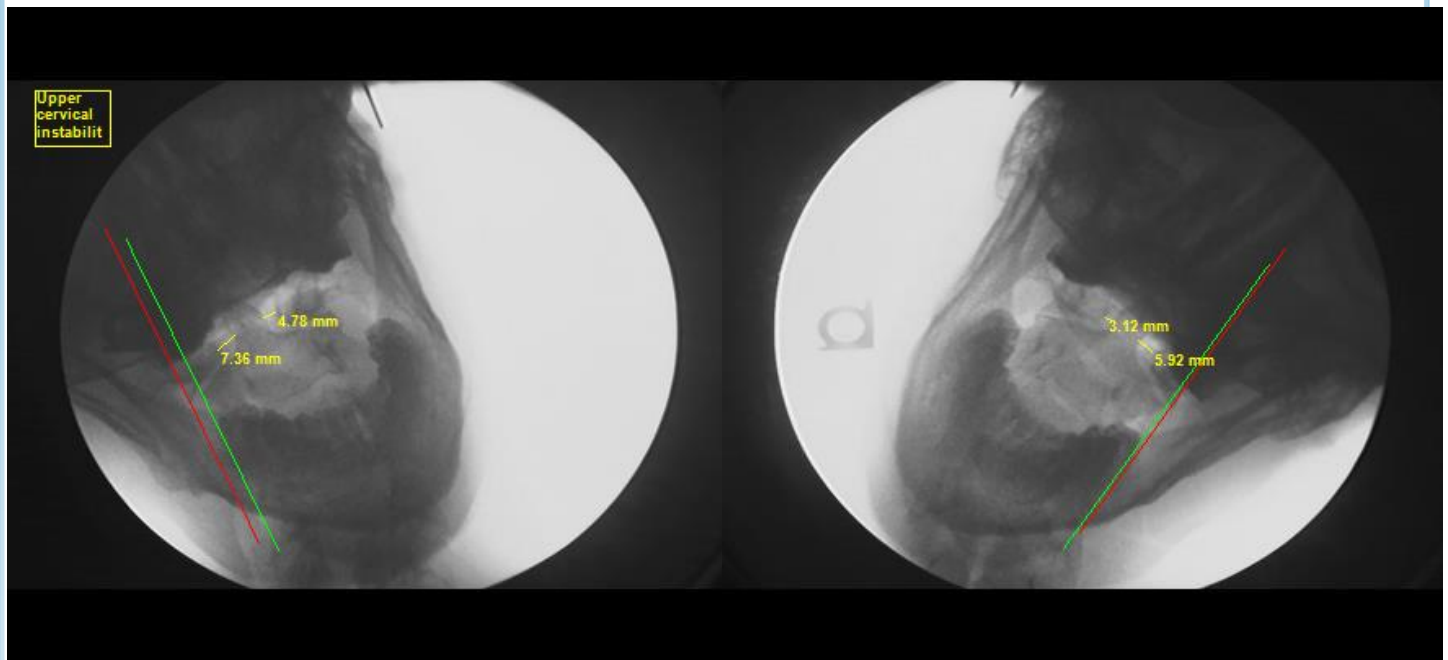
2727 Pine Street Unit 1, Boulder, Colorado 80302 303-938-9070

## X-RAY Report of Findings

## Front View of Your Upper Neck Bending to the Side (AP Open Mouth Left and Right Bending Views)

The green line represents the normal alignment where the side of Atlas (C1) vertebrae should be positioned on Axis (C2) vertebrae.

The red line represents the current position of your Atlas (C1) vertebrae.



X-ray Left

X-ray Right

X-ray Right

### Notes about your condition:

In this view, your head was tipped left and right to demonstrate motion of your Atlas (C1 Vertebrae) relative to your Axis (C2 Vertebrae). Ideally, there should be minimal lateral displacement of your Atlas bone relative to Axis.

For the left bending position, your spine demonstrates that the left side of your Atlas is shifted 5.2 mm left off of the Axis (C2). Your Atlas is also tipped  $28.8^\circ$  right relative to the Axis.

For the right bending position, your spine demonstrates that the right side of your Atlas is shifted 1.5 mm right off of the Axis (C2). Your Atlas is also tipped  $19.0^\circ$  left relative to the Axis.

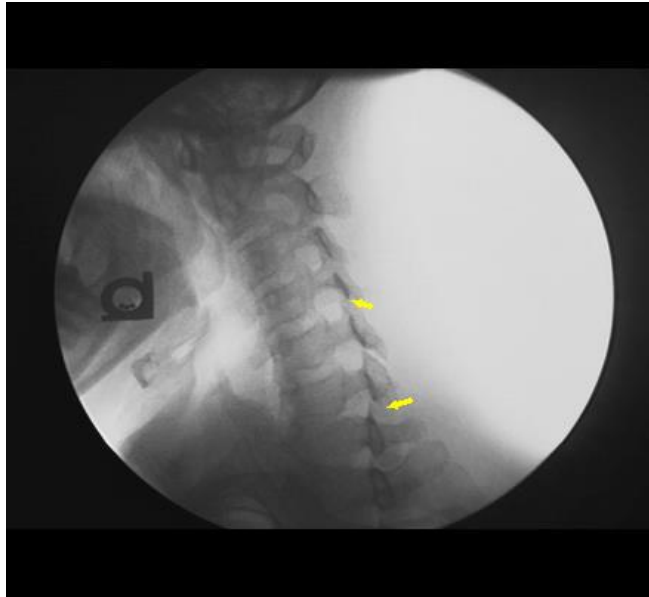# Katz Chiropractic & Rehab Clinic

2727 Pine Street Unit 1, Boulder, Colorado 80302 303-938-9070

## X-RAY Report of Findings

## Other View - oblique flex facet gap

oblique flex facet gap



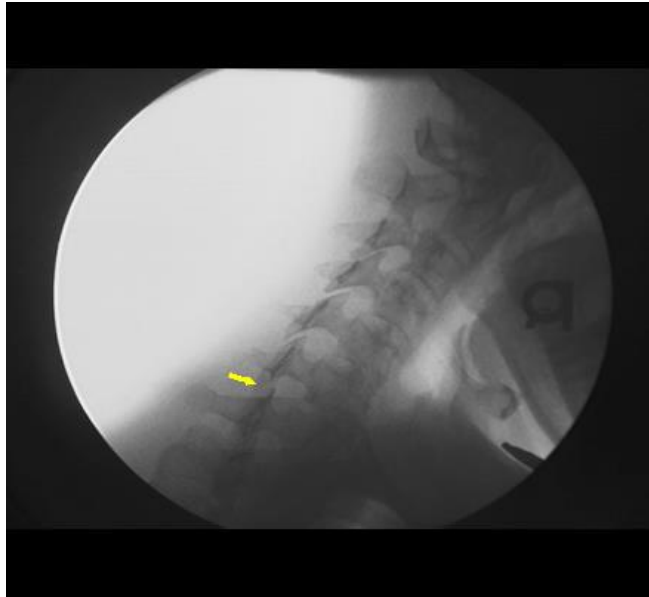
# Katz Chiropractic & Rehab Clinic

2727 Pine Street Unit 1, Boulder, Colorado 80302 303-938-9070

## X-RAY Report of Findings

## Other View - oblique flex facet gap

oblique flex facet gap





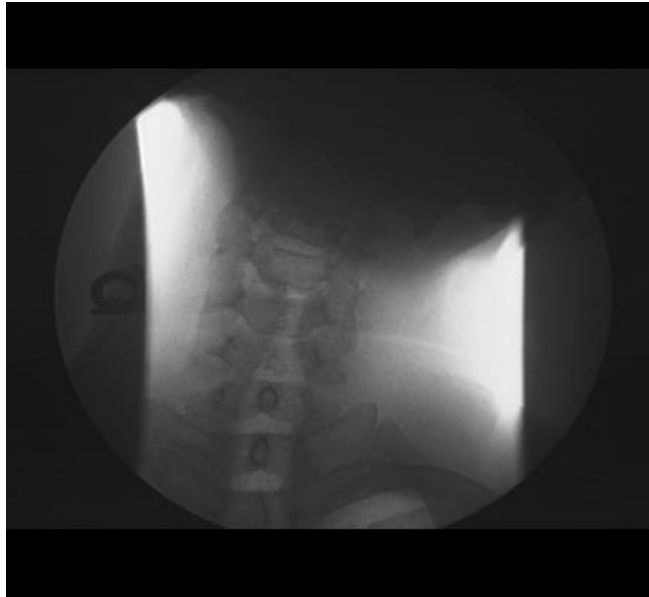
# Katz Chiropractic & Rehab Clinic

2727 Pine Street Unit 1, Boulder, Colorado 80302 303-938-9070

## X-RAY Report of Findings

## Other View - lateral flex

**lateral flex**



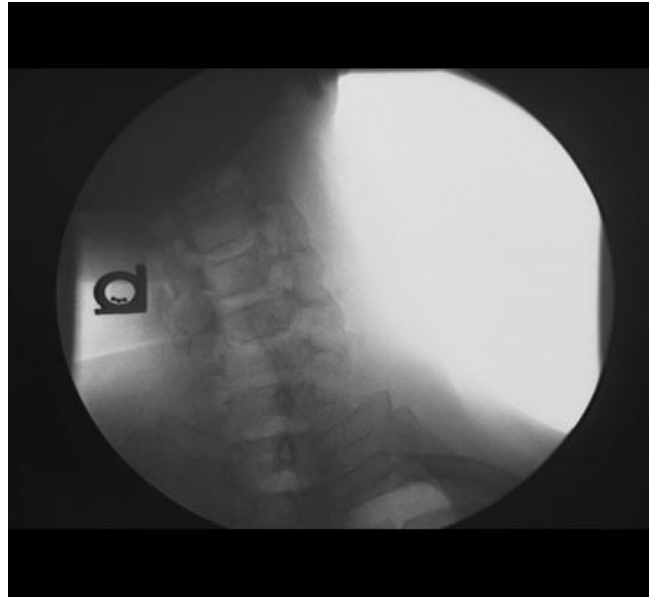
# Katz Chiropractic & Rehab Clinic

2727 Pine Street Unit 1, Boulder, Colorado 80302 303-938-9070

## X-RAY Report of Findings

## Other View - lateral flex

**lateral flex**



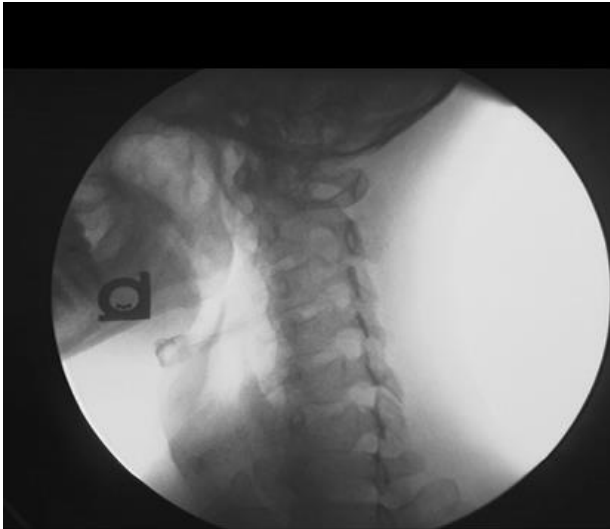# Katz Chiropractic & Rehab Clinic

2727 Pine Street Unit 1, Boulder, Colorado 80302 303-938-9070

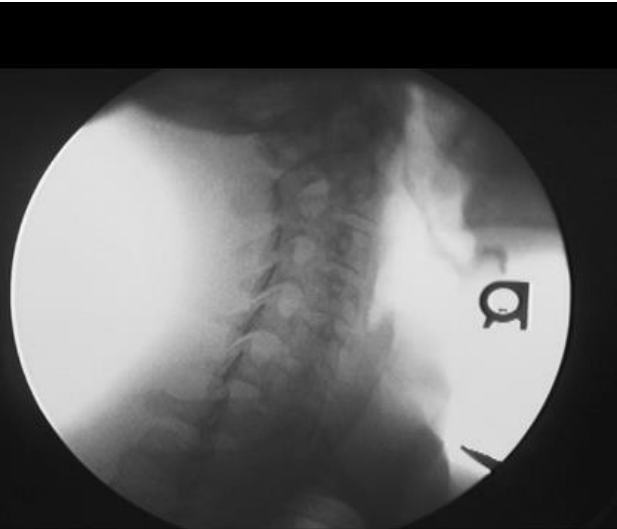## X-RAY Report of Findings

## Other View - Cervical Oblique

Cervical Left Oblique



Cervical Right Oblique



# Katz Chiropractic & Rehab Clinic

2727 Pine Street Unit 1, Boulder, Colorado 80302 303-938-9070

## X-RAY Report of Findings

## Summary

By looking at your x-ray views compared to the normal views in the preceding photographs, you get a visual idea of what is wrong with your spinal alignment, which Healthcare Practitioners term vertebral subluxations.

However, a visual image does not provide the details of your misalignments. Therefore, we have provided the following Table, which has normal values for the lateral x-ray views for segmental and global alignment compared to your segmental and global alignment. These sagittal (lateral view) values were determined using a geometric analysis of the positions of your vertebrae on each x-ray view.

## Cervical Spinal Level

Segments Analyzed	RRA Normal Values	RRA Patient Values	Difference From Normal	Segmental Translations
C1 to Horiz.	-29.0°	-26.9°	7.2%	
C2-C3	-10.0°	-1.5°	85.0%	-0.9 mm
C3-C4	-8.0°	-2.6°	67.5%	-2.1 mm
C4-C5	-8.0°	-12.5°	56.2%	-1.2 mm
C5-C6	-8.0°	0.3°	103.8%	0.4 mm
C6-C7	-8.0°	-8.7°	8.7%	-1.3 mm
Global Analysis		Normal Values	Patient Values	Diff. From Normal
ARA C2-C7		-42°	-25.1°	40.2%
Translation C2-C7		0 mm	5.1 mm	5.1 mm

RRA = Relative Rotational Angle of Measurement

ARA = Absolute Rotational Angle of Measurement

## Side View of Your Neck Flexed

In your spine when you tip your head down (flexion position), you show possible damage at the C6-C7 spinal levels.

## Side View of Your Neck Extended

In the head backwards position (extension position), your spine demonstrates possible ligament damage at the C4-C5, C5-C6, C6-C7 spinal levels.

# Katz Chiropractic & Rehab Clinic

2727 Pine Street Unit 1, Boulder, Colorado 80302 303-938-9070

## X-RAY Report of Findings

## Summary

### Neutral Upper Neck Values

Global Analysis	Normal Values	Patient Values	Difference From Normal	Clinical Significance
C0-C1 Lat. Flex. Angle	0°	1.9°	1.9°	WNL
C1-C2 Lat. Flex. Angle	0°	0.6°	0.6°	WNL
C2-C3 Lat. Flex. Angle	0°	Not Digitized	n/a	
Left C1-C2 "overhang" margin	0 mm	0.7 mm	0.7 mm	WNL
Right C1-C2 "overhang" margin	0 mm	1.0 mm	1.0 mm	WNL
C2 Axial Spinous Rotation	0°	Not Digitized	n/a	

WNL = Within Normal Levels



# Katz Chiropractic & Rehab Clinic

2727 Pine Street Unit 1, Boulder, Colorado 80302 303-938-9070

## X-RAY Report of Findings

## Important Information

### Disclaimer:

THE CONTENTS OF THIS POSTURERAY® REPORT ARE NOT A SUBSTITUTE FOR YOUR HEALTH CARE PROVIDER'S INDEPENDENT AND THOROUGH DIAGNOSIS. The findings of this PostureRay® Report are determined by analyzing points on a digitized radiograph which were chosen by your health care provider. The accuracy and quality of the results produced by this PostureRay® Report are entirely dependent upon your health care provider's ability to see and choose the correct landmarks on the digitized radiograph. THEREFORE, WE CANNOT AND DO NOT WARRANT OR GUARANTEE THE ACCURACY, COMPLETENESS OR RELEVANCY OF ANY INFORMATION OR RESULTS PROVIDED IN THIS POSTURERAY® REPORT. As with any clinical information, the information contained in the PostureRay® Report must be read, reviewed and approved by a health care provider. Your health care provider's signature below demonstrates that your health care provider read, reviewed and approved the findings in this PostureRay® Report before making it available to you. PostureCo, who owns PostureRay, is not responsible for the examinations, analysis, diagnosis, and treatment provided by your health care provider.

---

Evan Katz D.C.  
Katz Chiropractic & Rehab Clinic  
2727 Pine Street Unit 1  
Boulder, Colorado  
80302

# Katz Chiropractic & Rehab Clinic

2727 Pine Street Unit 1, Boulder, Colorado 80302 303-938-9070

## X-RAY Report of Findings

## References

- [1] Harrison DD, Janik TJ, Troyanovich SJ, Holland B. Comparisons of Lordotic Cervical Spine Curvatures to a Theoretical Ideal Model of the Static Sagittal Cervical Spine. *Spine* 1996;21(6):667-675.
- [2] Harrison DD, Harrison DE, Janik TJ, Cailliet R, Haas JW, Ferrantelli J, Holland B. Modeling of the Sagittal Cervical Spine as a Method to Discriminate Hypo-Lordosis: Results of Elliptical and Circular Modeling in 72 Asymptomatic Subjects, 52 Acute Neck Pain Subjects, and 70 Chronic Neck Pain Subjects. *Spine* 2004; 29(22):2485-2492.
- [3] Harrison DE, Janik TJ, Harrison DD, Cailliet R, Harmon S. Can the Thoracic Kyphosis be Modeled with a Simple Geometric Shape? The Results of Circular and Elliptical Modeling in 80 Asymptomatic Subjects. *J Spinal Disord Tech* 2002; 15(3): 213-220.
- [4] Harrison DD, Harrison DE, Janik TJ, Cailliet R, Haas JW. Do Alterations in Vertebral and Disc Dimensions Affect an Elliptical Model of the Thoracic Kyphosis? *Spine* 2003; 28(5): 463-469.
- [5] Janik TJ, Harrison DD, Cailliet R, Troyanovich SJ, Harrison DE. Can the Sagittal Lumbar Curvature be Closely Approximated by an Ellipse? *J Orthop Res* 1998; 16(6):766-70.
- [6] Harrison DD, Cailliet R, Janik TJ, Troyanovich SJ, Harrison DE, Holland B. Elliptical Modeling of the Sagittal Lumbar Lordosis and Segmental Rotation Angles as a Method to Discriminate Between Normal and Low Back Pain Subjects. *J Spinal Disord* 1998; 11(5): 430-439.
- [7] Harrison DE, Harrison DD, Cailliet R, Troyanovich SJ, Janik TJ. Cobb Method or Harrison Posterior Tangent Method: Which is Better for Lateral Cervical Analysis? *Spine* 2000; 25: 2072-78.
- [8] Harrison DE, Cailliet R, Harrison DD, Janik TJ, Holland B. Centroid, Cobb or Harrison Posterior Tangents: Which to Choose for Analysis of Thoracic Kyphosis? *Spine* 2001; 26(11): E227-E234.
- [9] Harrison DE, Harrison DD, Janik TJ, Harrison SO, Holland B. Determination of Lumbar Lordosis: Cobb Method, Centroidal Method, TRALL or Harrison Posterior Tangents? *Spine* 2001; 26(11): E236-E242.
- [10] Harrison DE, Holland B, Harrison DD, Janik TJ. Further Reliability Analysis of the Harrison Radiographic Line Drawing Methods: Crossed ICCs for Lateral Posterior Tangents and AP Modified Risser-Ferguson. *J Manipulative Physiol Ther* 2002; 25: 93-8.
- [11] Harrison DE, Harrison DD, Colloca CJ, Betz J, Janik TJ, Holland B. Repeatability of Posture Overtime, X-ray Positioning, and X-ray Line Drawing: An Analysis of Six Control Groups. *J Manipulative Physiol Ther* 2003; 26(2): 87-98.
- [12] Kauffman JM. Diagnostic Radiation: Are the risks exaggerated? *J Amer Phys Surg* 2003; 8(2): 54-55.
- [13] Cohen BL. Test of the linear-no threshold theory of radiation carcinogenesis for inhaled radon decay products. *Health Physics* 1995;68(2):157-174.
- [14] Cohen BL. The cancer risk from low level radiation: a review of recent evidence. *Med Sent* 2000;5:128-131.
- [15] Cohen BL. Cancer risk from low-level radiation. *AJR* 2002;179(5):1137-43.
- [16] Cohen BL. Catalog of risks extended and updated. *Health Physics* 1991; 61(3):317-335.
- [17] Walker JS. Permissible dose: A history of radiation protection in the 20th century. Berkeley, Calif: University of California Press, Berkeley, 2000.
- [18] Harrison DE, Harrison DD, Haas JW. Structural rehabilitation of the cervical spine. Evanston, WY: Harrison CBP? Seminars, Inc., 2002.
- [19] Harrison DE, Harrison DD, Haas JW, Betz J, Oakley PA. CBP? Structural rehabilitation of the lumbar spine. Evanston, WY: Harrison CBP? Seminars, Inc., 2005.
- [20] Regano LJ, Sutton RA. Radiation dose reduction in diagnostic X-ray procedures. *Phys Med Biol* 1992;37(9):1773-1788.
- [21] Luckey TD. Radiation Hormesis. Boca Raton: CRC Press, 1991;5:228-230.
- [22] Luckey TD. Nurture with ionizing radiation: a provocative hypothesis. *Nutrition Cancer* 1999; 34(1):1-11.
- [23] Sherwood T. 100 years' observation of risks from radiation for British male radiologists. *Lancet* 2001; 358:604.
- [24] Stokes IAF, Bevins TM, Lunn RA. Back surface curvature and measurement of lumbar spinal motion. *Spine* 1987;12:355-361.
- [25] Johnson GM. The correlation between surface measurement of head and neck posture and the anatomic position of the upper cervical vertebrae. *Spine* 1998;23:921-927.
- [26] Refshauge KM, Goodsell M, Lee M. The relationship between surface contour and vertebral body measures of upper spine curvature. *Spine* 1994;19:2180-2185.
- [27] Mosner EA, Bryan JM, Stull MA, Shippee R. A comparison of actual and apparent lumbar lordosis in black and white adult females. *Spine* 1989;14:310-331.
- [28] Committee to Assess Health Risks from Exposure to Low Levels of Ionizing Radiation. Health risks from exposure to low levels of ionizing radiation: BEIR VII Phase 2. National Research Council. Washington DC: National Academies Press, 2005.
- [29] Kant K, Chauhan RP, Sharma GS, Chakarvarti SK. Hormesis in animals exposed to low-level ionizing radiation. *Inter J Low Rad* 2003; 1(1):76-87.
- [30] Feinendegen LE. Evidence for beneficial low level radiation effects and radiation hormesis. *Br J Radiol* 2005;78:3-7.
- [31] Parsons PA. Hormesis: an adaptive expectation with emphasis on ionizing radiation. *J Appl Tox* 2000;20:103-112.
- [32] Pollycove M. The issue of the decade: hormesis. *Eur J Nucl Med* 1995;22:399-401.
- [33] Pollycove M. Nonlinearity of radiation health effects. *Env Health Persp* 1998;106:363-368.
- [34] Luckey TD. Hormesis with Ionizing Radiation. CRC Press, Boca Raton, FL, 1980:
- [35] Cohen BL. Problems in the radon vs. lung cancer test of the linear no-threshold theory and a procedure for resolving them. *Health Phys* 1997;72:623-628.

# Katz Chiropractic & Rehab Clinic

2727 Pine Street Unit 1, Boulder, Colorado 80302 303-938-9070

## X-RAY Report of Findings

## References

- [36] Cohen BL. Updates and extensions to tests of the linear no-threshold theory. *Technology* 2000;7:657-672.
- [37] Frigerio NA, Eckerman KF, Stowe RS. Carcinogenic hazard from low-level, low-rate radiation, Part I. Rep.ANL/ES-26.Argonne Nat.Lab 1973.
- [38] Jagger J. Natural background radiation and cancer death rate in Rocky Mountain and Gulf Coast States. *Health Phys* 1998;75:428-434.
- [39] Kostyuchenko VA, Krestina L. Long-term irradiation effects in the population evacuated from the east-Urals radioactive trace area. *Sci Total Environ* 1994;142:119-125.
- [40] Matanoski, G. M. Health effect of low level radiation in shipyard workers: final report. Report no. DOE DE-AC02-79 EV10095. 1991. Washington, DC, US Dept of Energy.
- [41] Hickey RJ, Bowers EJ, Clelland RC. Radiation hormesis, public health, and public policy: a commentary. *Health Phys* 1983;44:207-219.
- [42] Tubiana M. The carcinogenic effect of low doses: the validity of the linear no-threshold relationship. *Int J Low Rad* 2003;1:1-33.
- [43] Cameron JR. Moderate dose rate ionizing radiation increases longevity. *Br J Radiol* 2005;78:11-13.
- [44] Cameron JR. Radiation increased the longevity of British radiologists. *Br J Radiol* 2002;75:637-640.
- [45] Cameron JR. Longevity is the most appropriate measure of health effects of radiation. *Radiol* 2003;229:14-15.
- [46] Cameron JR. Is radiation an essential trace energy? *Physics and Society* 2001;Oct:<http://www.aps.org/units/fps/newsletters/2001/october/a5oct01.html>
- [47] Parsons PA. Radiation hormesis: an ecological and energetic perspective. *Med Hypoth* 2000;57:277-279.
- [48] Luckey TD. Radiation hormesis in cancer mortality. *Chi Med J* 1994;107:627-630.